

## Slide thyrocricotracheoplasty: a novel surgical technique for congenital laryngeal atresia

Seong Min Kim · Seok Joo Han · Hong Sik Choi ·  
Yong Taek Nam · Jung Tak Oh · Seung Hoon Choi

Accepted: 5 April 2007 / Published online: 24 May 2007  
© Springer-Verlag 2007

**Abstract** The aim of this study was to introduce a new surgical technique for the correction of congenital laryngeal atresia. A female baby had laryngeal atresia at birth and received emergency tracheostomy at another hospital. The baby visited our hospital at 7 months of age for corrective surgery of airway obstruction. We used a new surgical technique for reconstruction of her airway, the slide thyrocricotracheoplasty, which was a modification of slide tracheoplasty and anterior cricoid split. The extubation was successful at the postoperative fifth day, and the baby was discharged on the 33rd day after operation. The serial follow-up bronchoscopy on the fourth and 18th postoperative months revealed good healing and normal growth of tissue at operation site without stenosis and granulation. Slide thyrocricotracheoplasty produced a desirable result and offered the same advantages as slide tracheoplasty. The authors believe that this technique offers an efficient surgical procedure for the single-staged correction of congenital laryngeal atresia.

**Keywords** Laryngeal atresia · Congenital tracheal stenosis · Slide thyrocricotracheoplasty · Slide tracheoplasty

### Introduction

Laryngeal atresia is rare, but uniformly fatal disease in untreated newborn. There have been many surgical options for correction of laryngeal atresia, but no surgical procedure has yet provided a favorable outcome. Since the first report of Tsang [1], slide tracheoplasty for correction of congenital tracheal stenosis has shown excellent short and midterm outcomes with shorter period of the intubation and low incidence of complication such as anastomotic stenosis. It was reported that modification of slide tracheoplasty is an efficient surgical procedure for the correction of more severe congenital upper airway stenosis such as congenital cricotracheal stenosis [2]. Here we report one case of female infant with congenital laryngeal atresia in whom, stenosis was not confined to trachea but extended to cricotracheal cartilage and even thyroid cartilage with complete obstruction of subglottic area. We introduced a new surgical technique—slide thyrocricotracheoplasty, modified and extended form of slide tracheoplasty for the correction of airway obstruction.

### Case report

A 7-month-old female baby was admitted into our hospital for corrective surgery of airway obstruction. She was delivered via C-section at 40 weeks of gestation weighing 3,320 g. Her mother had polyhydramnios. The baby had received emergency tracheostomy at another hospital

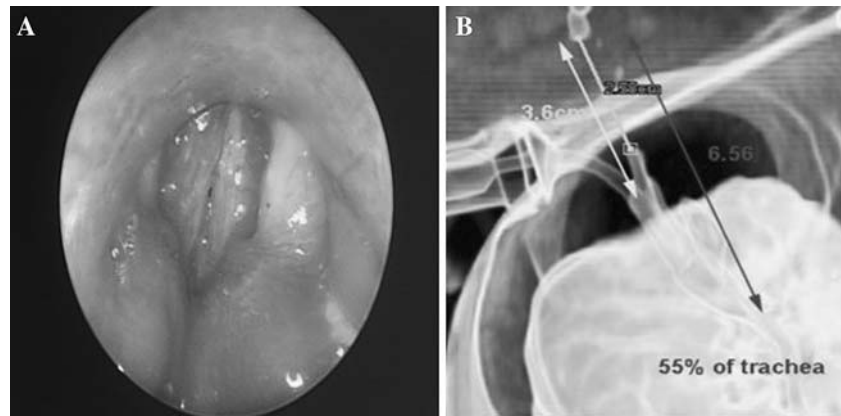
---

S. M. Kim · S. J. Han (✉) · J. T. Oh · S. H. Choi  
Division of Pediatric Surgery, Department of Surgery,  
Yonsei University College of Medicine,  
Shinchon-dong 134, Seodaemun-gu,  
120-752 Seoul, South Korea  
e-mail: sjhan@yumc.yonsei.ac.kr

H. S. Choi  
Department of Otolaryngology,  
Yonsei University College of Medicine,  
Seoul, South Korea

Y. T. Nam  
Department of Anesthesiology,  
Yonsei University College of Medicine,  
Seoul, South Korea

**Fig. 1** Preoperative bronchoscopy (a) and 3D chest CT scan (b) showing almost occlusive changes of upper tracheal area from vocal cord to tracheostomy site (narrowing segment = 2.58 cm/ 6.56 cm = 39% of trachea)



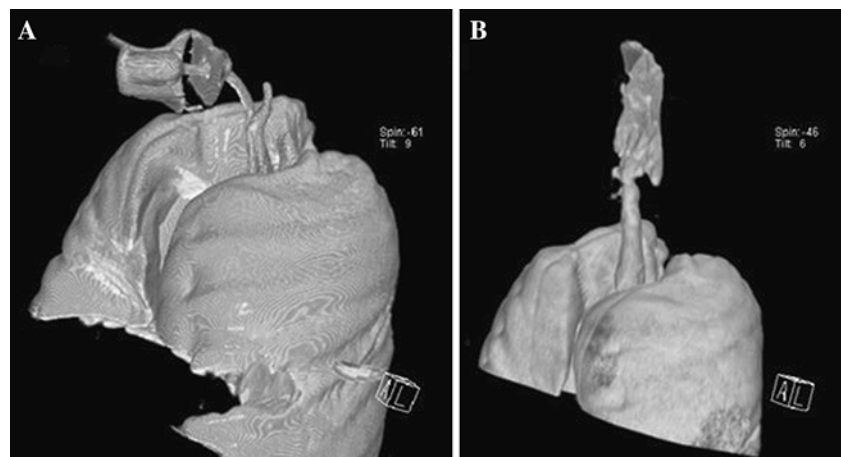
immediately after birth due to severe chest retraction and cyanosis following failure of endotracheal intubation. Rigid bronchoscopy revealed complete obstruction of airway at the subglottic level (Fig. 1a). She had multiple anomaly including patent ductus arteriosus, atrial septal defect (5.3 mm in diameter), pectus excavatum, cleft palate and thoracic spina bifida. Chromosomal study showed normal 46xx karyotype. The 3D chest CT showed that the occlusive change was extended downward to upper trachea just above the tracheostomy site (Fig. 1b). We decided to perform “slide upper-airway plasty” rather than “cartilage autograft” or “patch tracheoplasty” based on our own experience of treatment for congenital cricotracheal stenosis using slide cricotracheoplasty [2]. Postoperative course was uneventful. Extubation was performed on the fifth postoperative day, and the patient was discharged on 33rd postoperative day. Compared with preoperative CT scan, postoperative CT scan showed marked improvement of airway diameter (Fig. 2). The patient was admitted two times for correction of pectus excavatum during the fourth and 18th postoperative months, when she received follow-up bronchoscopy, which revealed desirable healing

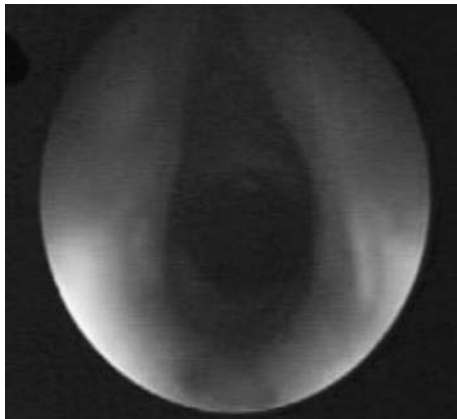
and normal growth of tissue at operation site without stenosis and granulation (Fig. 3).

#### Surgical technique

After the inhalation of anesthesia through the tracheostomy tube, the neck was extended, a transverse collar neck incision was made with circular skin incision surrounding the tracheostomy site. After transection of the platysma and strap muscle, the upper airway was exposed from the thyroid cartilage to the thoracic inlet. The isthmus of the thyroid gland was mobilized from the trachea, clamped and divided. The isthmuses on each side were then sutured with continuous interlocking 5-0 Vicryl sutures. Lateral retraction of both thyroid lobes exposed the upper border of the thyroid cartilage, cricoid cartilage and the upper tracheal rings. The extent of the stenotic segment was determined accurately by intraoperative bronchoscopic observation of a 24-gauge fine needle tip inserted from the outside into the airway, which showed that laryngeal atresia was just below true vocal cord. There was a grossly and normally developed trachea below tracheostomy site. After defining the

**Fig. 2** a Preoperative 3D chest CT scan showing complete narrowing of laryngotrachea. Lower limit of stenosis looked like a blind pouch. b Postoperative 3D chest CT scan taken at third month after slide thyrocricotracheoplasty showing patent trachea





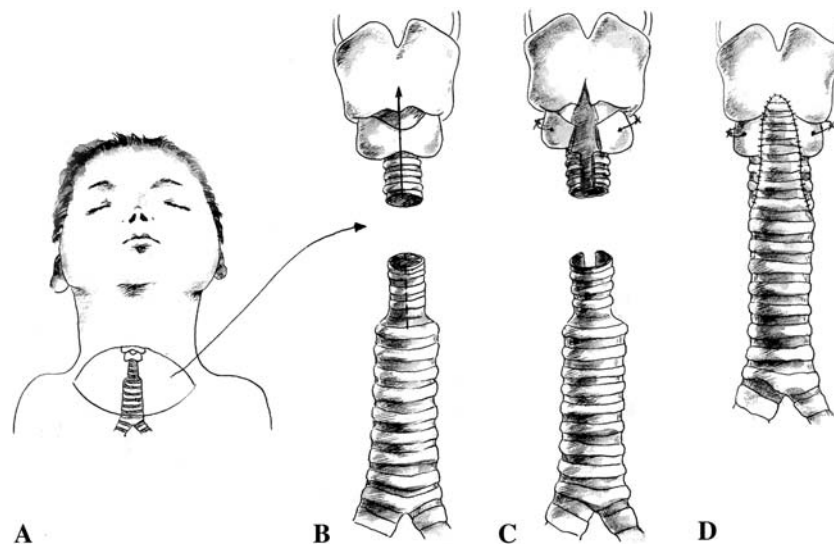
**Fig. 3** Follow-up bronchoscopy on the 18th postoperative month revealed desirable healing and normal growth of tissue at operation site without stenosis and granulation

obstructive segment, the trachea was divided at the level of the midpoint of the obstructive segment with #15 blade. The cephalad portion of the stenotic trachea, the cricoid and lower one third of thyroid cartilage just below vocal cord were split on their anterior surface. The splitting showed markedly hypertrophied cricoid and thyroid cartilage that completely obstructed the lumen of the larynx. The caudal portion of the stenotic trachea was similarly split on its posterior wall and extended until the normal segment of the trachea was encountered caudally (Fig. 4). Posterior dissection of the tracheal wall allowed sliding of

both segments. The excessive hypertrophied portion of the anterior cricoid arch and lower part of thyroid cartilage were resected, and the right-angled corners of two segments were trimmed. Because of the stiffness of the cricoid cartilage and thyroid cartilage, two lateral traction sutures of cricoid cartilage (to prevertebral fascia) were necessary to maintain enough space to accommodate the slide caudal portion of the trachea. After flexing the neck, the superior segment was anastomosed, first posteriorly, with interrupted 5-0 Prolene sutures, to the inferior segment. The tracheostomy tube of the operative field was exchanged for endotracheal tube, by first passing a pediatric feeding tube through the upper portion of the trachea and out of the baby’s mouth as a guide. The endotracheal tube was inserted under the guidance of the feeding tube, into the trachea, past the posterior anastomosis, and then the anterior anastomosis was completed with interrupted 5-0 Prolene sutures. Previous tracheostomy site was closed after resecting the scar tissue. Air-leakage test confirmed airtightness of the anastomosis. The cervical incision was closed layer by layer and two SILASTIC® (Dow Corning, Midland, MI) drains were inserted.

**Discussion**

Congenital laryngeal atresia is one of the rarest congenital, life-threatening anomalies of the neonate unless an



**Fig. 4 a** The baby was placed with her neck extended and a transverse collar incision made. **b** After dividing the stenotic segment at the midpoint of the stenosis, the cephalad portion of the stenotic trachea, the cricoid, and part of thyroid cartilage (arrow) were split on their anterior surface. The caudal segment of the stenotic trachea was similarly split on its posterior wall and extended until the normal segment of the trachea was encountered. **c** The excessive cartilage of

the anterior cricoid plate was resected and the vertical split of the cricoid cartilage was kept enlarged with two lateral traction sutures of cricoid cartilage to the prevertebral fascia to accommodate the caudal portion of the trachea. **d** The upper segment then was slid behind the lower segment with a wedge from the upper segment placed into the split made on the lower. The anastomosis was constructed with multiple-interrupted sutures

aggressive approach is made for survival. Until now, there is no established surgical procedure for congenital laryngeal atresia. In these patients, the cricoid is a complete ring narrowing the tracheal lumen to a “pinpoint funnel” requiring immediate intubation. There are only a few reported cases of congenital laryngeal atresia that achieved long term survival [3], in which case anterior cricoid split and interposition of autologous cartilage was performed. A variety of surgical methods have been tried including resection with end-to-end anastomosis [4, 5], cartilaginous augmentation graft [6], pericardial patch augmentation [7], esophageal wall graft [8] and slide tracheoplasty [1, 9, 10] for correction of congenital laryngotracheal obstructive lesion, but there is still much debate about superiority. The most serious problem after tracheal surgery is the formation of granulation tissue. Schweizer [3] suggested that it originates from intubation tip or caused by eight-shaped tracheal lumen due to the springing force of the incised cartilaginous ring. Kim [11] reported 13 cases of congenital tracheal stenosis and suggested that formation of granulation tissue was maximal among patients received patch tracheoplasty. Since Tsang [1] had reported slide tracheoplasty for the first time, various reports about favorable results of the slide tracheoplasty were presented. Tsugawa [12] reported that it is better than traditional rib cartilage graft in terms of function and complication such as anastomotic stenosis or granulation tissue formation. Schweizer [3] recommends autologous cartilage insertion after anteroposterior cricoid split. Previously, we reported one case in whom slide cricothyroplasty was performed [2], which was modified slide tracheoplasty and anterior cricoid split for treatment of congenital cricotracheal stenosis. The patient in this report demonstrated that the upper limit of obstructive segment is as far as just beneath vocal cord. Therefore, part of the thyroid cartilage, cricothyroid ligament, cricoid cartilage had to be incised to halve the stenosis. But voice change was not observed after operation due to limited manipulation of the subglottis in slide-type tracheoplasty. Furthermore, resection of trachea with end-to-end anastomosis was not possible due to long (39% of trachea), and severe (pin-point hall) stenosis, which is known to cause considerable anastomotic tension after end-to-end anastomosis. According to Wright and colleagues [13], length of stenosis above 4 cm, preoperative tracheostomy, pediatric age, reoperation and laryngotracheal resection, are all independent risk factors for anastomotic failure in tracheal surgery. The patient in this report is the first reported case in which modified and extended form of slide tracheoplasty (thyrocricotracheoplasty) was performed for correction of congenital laryngeal atresia. Slide

tracheoplasty has many advantages: the stenotic segment is halved with less anastomotic tension; the circumference of the stenotic trachea is doubled; the luminal cross section is quadrupled [9, 10]; the approach is cervical with or without partial sternotomy without cardiopulmonary bypass [9, 10]; and the blood supply from lateral side is not impaired, which results in excellent healing and minimal complications. Furthermore, the normal ciliated native epithelium is used for reconstruction [9, 10], which minimizes granulation tissue formation. “Physiologic” growth of the reconstructed hemitracheal rings after the slide tracheoplasty also has been shown [14]. The authors believe that our new operative technique—slide thyrocricotracheoplasty—is the preferred operative method for severe, high-grade (Myer-Cotton staging IV, McCaffrey staging III) congenital tracheal stenosis—congenital laryngeal atresia.

## References

1. Tsang V, Murday A, Gillbe C et al (1989) Slide tracheoplasty for congenital funnel-shaped tracheal stenosis. *Ann Thorac Surg* 48:632–635
2. Han SJ, Kim YH, Kim MJ et al (2002) Slide cricotracheoplasty: a novel surgical technique for congenital cricotracheal stenosis. *J Pediatr Surg* 37:E36
3. Schweizer P, Berger S, Petersen M et al (2005) Tracheal surgery in children. *Eur J Pediatr Surg* 15:236–242
4. Cantrell JR, Guild HG (1964) Congenital stenosis of the trachea. *Am J Surg* 108:297–305
5. Mattingly WT Jr, Belin RP, Todd EP (1981) Surgical repair of congenital tracheal stenosis in an infant. *J Thorac Cardiovasc Surg* 81:738–740
6. Ein SH, Friedberg J, Williams WG et al (1982) Tracheoplasty—a new operation for complete congenital tracheal stenosis. *J Pediatr Surg* 17:872–878
7. Kimura K, Mukohara N, Tsugawa C et al (1982) Tracheoplasty for congenital stenosis of the entire trachea. *J Pediatr Surg* 17:869–871
8. Grillo HC (1973) Reconstruction of the trachea. Experience in 100 consecutive cases. *Thorax* 28:667–679
9. Grillo HC (1994) Slide tracheoplasty for long-segment congenital tracheal stenosis. *Ann Thorac Surg* 58:613–619
10. Grillo HC, Wright CD, Vlahakes GJ et al (2002) Management of congenital tracheal stenosis by means of slide tracheoplasty or resection and reconstruction, with long-term follow-up of growth after slide tracheoplasty. *J Thorac Cardiovasc Surg* 123:145–152
11. Kim HK, Kim YT, Sung SW et al (2004) Management of congenital tracheal stenosis. *Eur J Cardiothorac Surg* 25:1065–1071
12. Tsugawa C, Nishijima E, Muraji T et al (2003) Tracheoplasty for long segment congenital tracheal stenosis: analysis of 29 patients over two decades. *J Pediatr Surg* 38:1703–1706
13. Wright CD, Grillo HC, Wain JC et al (2004) Anastomotic complications after tracheal resection: prognostic factors and management. *J Thorac Cardiovasc Surg* 128:731–739
14. Macchiarini P, Dulmet E, de Montpreville V et al (1997) Tracheal growth after slide tracheoplasty. *J Thorac Cardiovasc Surg* 113:558–566