Thoracoscopic Repair of Congenital Diaphragmatic Hernia

Hye Kyung Chang, Jung-Tak Oh, Seung Hoon Choi, Seok Joo Han

Division of Pediatric Surgery, Department of Surgery,
Yonsei University College of Medicine

Background

<u>Treatment of Congenital Diaphragmatic hernia (CDH)</u>

I.surgical repair via subcostal transverse laparotomy
II.laparoscopic repair since 1995
III.thoracoscopic repair since 2001 in western report
: tolerance to one lung ventilation depending on pulmonary function

in Korea,
only one case report of thoracoscopic repair of right sided CDH in 2007

Purpose

presentation of two cases of thoracoscopic repair of left sided CDH

✓ 3-month-old boy with delayed presentation of CDH

✓ neonate with prenatal presentation of CDH on U/S

CASE I

3-month-old boy , 7.6 kg
C/C : continuous irritability
referred from other hospital with diagnosis of diaphragmatic hernia, Lt.

<u>Chest and abdominal X-ray</u>

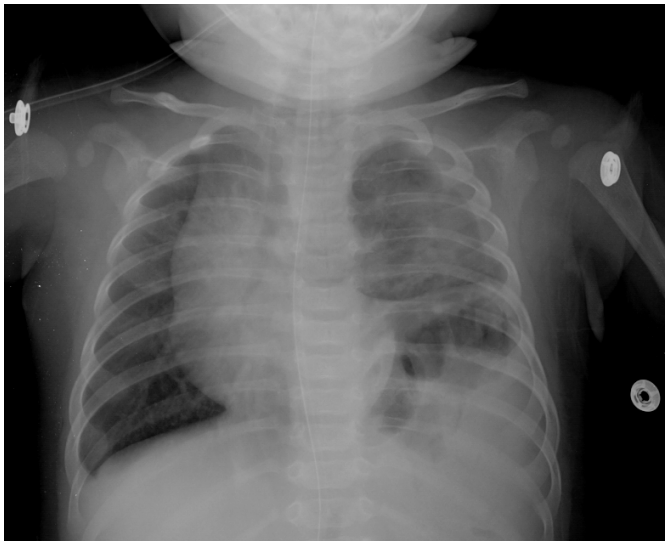

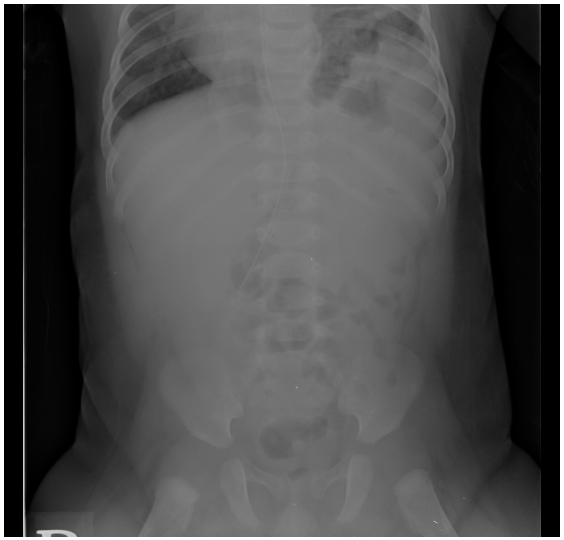

herniated bowel shadow in the left lower lung field
decreased bowel gas in abdomen
corresponding with Bochdalek hernia

Thoracoscopic repair of left sided CDH

single lung ventilation by CO_2 inflation

herniation of the stomach, small bowel and liver
in the left lower thoracic cavity

no adhesion between herniated organs and thoracic cavity or lung

reduction of the herniated organs to the abdominal cavity : simple & easy

four interrupted, non-absorbable sutures to close the diaphragmatic defect

operating time : 162 minutes

postoperative course : uneventful (discharge on POD#5)

독도는 우리 땅

Postop. Chest and Abdominal X-ray

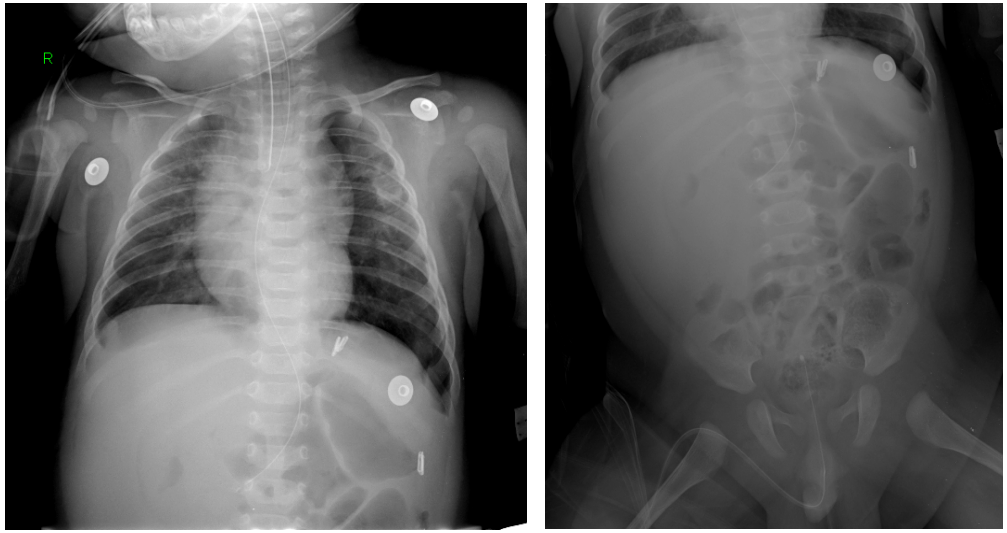

Immediate postop.

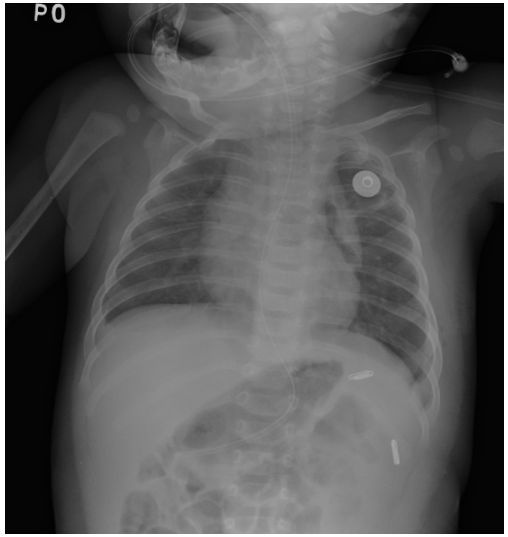

Extubation on POD #1

수술 3주 후 OPD f/u

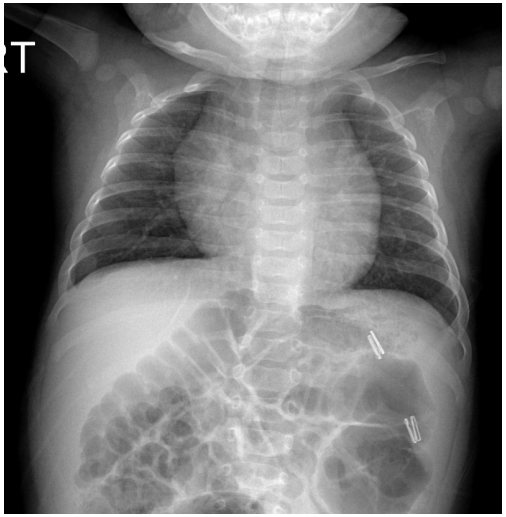

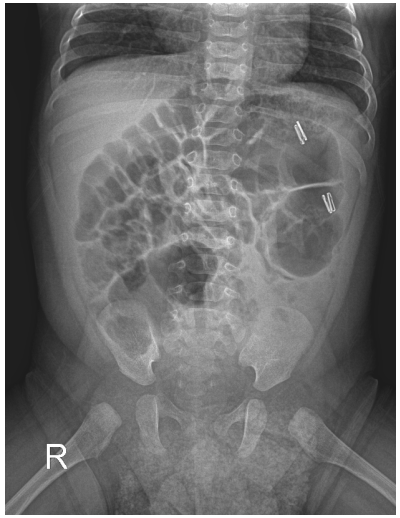

CASE II

F/ 1 day
IUP 32 wks, birth weight 1.795 kg
C-sec delivered d/t PROM, preterm labor
Apgar score 1' - 4, 5' - 6
Intubation, ambu bagging
Prenatal U/S : r/o CDH, r/o CCAM, hydramios on IUP 31 wks

<u>Chest and abdominal x-ray</u>

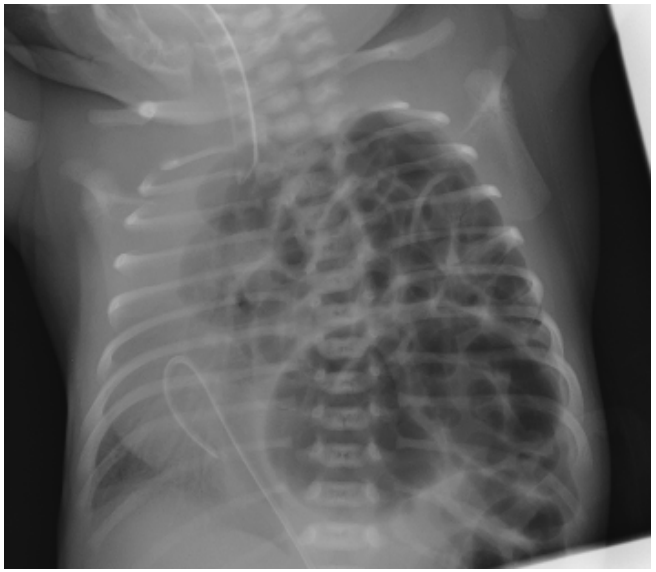

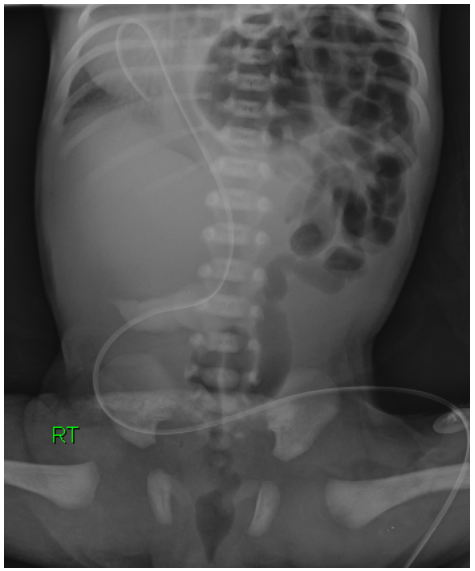

Operation

Thoracoscopic repair of left sided CDH
Broviac catheter insertion

total operating time : 325 minutes
operating time of thoracoscopic CDH repair : 160 minutes

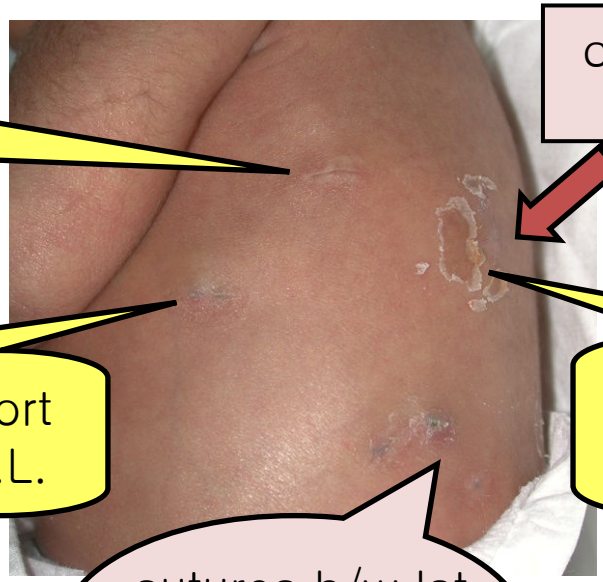

독도는 우리 땅

Postoperative X-ray findings

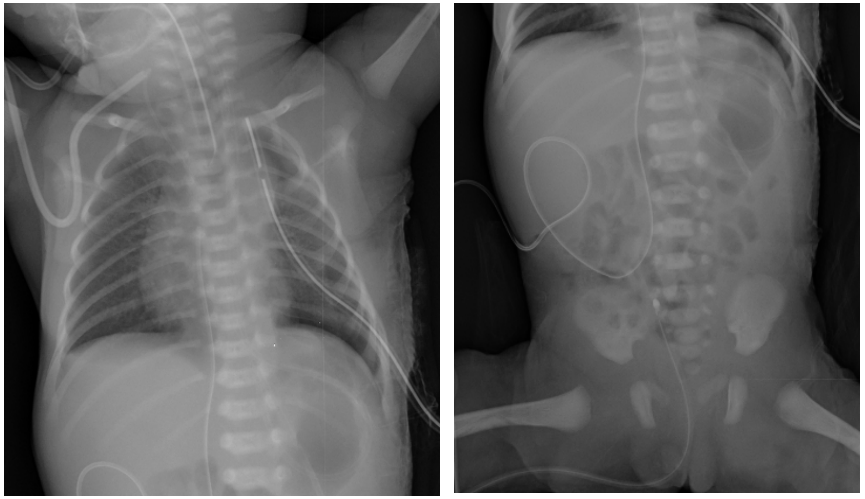

Immediate postop.

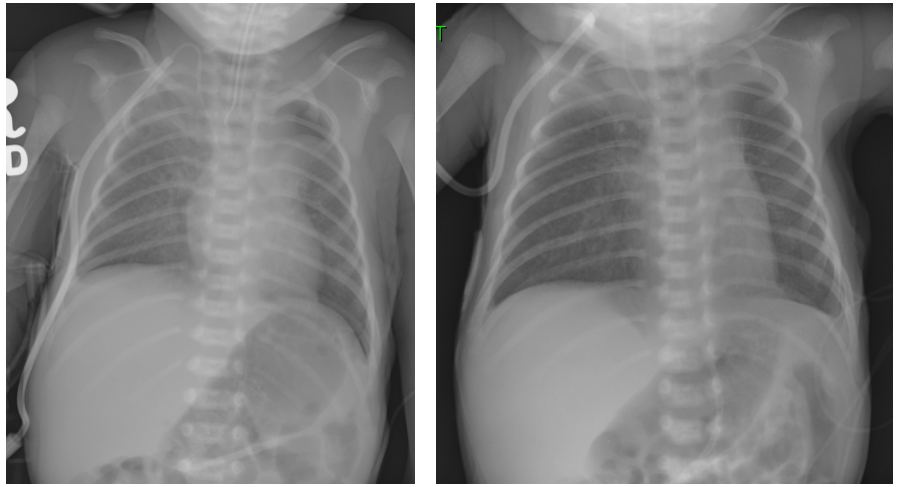

Chest tube removal on POD #3

Extubation on POD #6

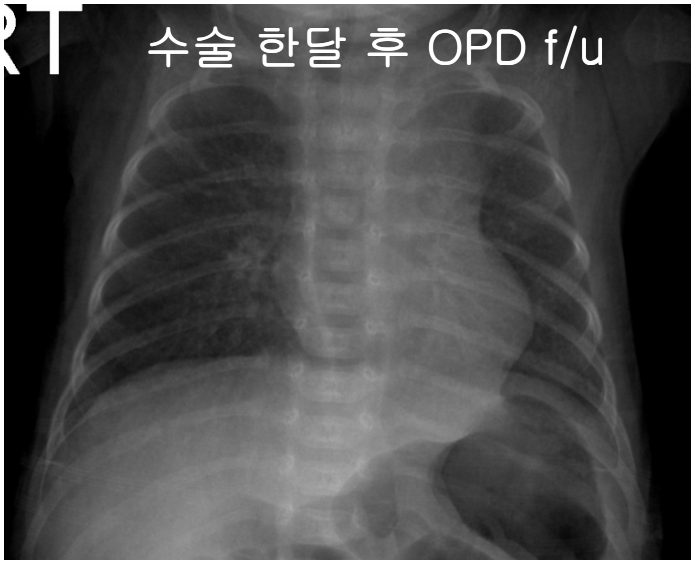

Conclusion

- Thoracoscopic hernioplasty is easy, feasible and safe technique for delayed CDH without pulmonary comorbidity in infants or children.

- Premature baby with adequate fetal pulmonary development and late presentation of diaphragmatic hernia may be considered as indication of thoracoscopic repair of CDH.

- In considering
  1) morbidity and pain on postop. course of thoracotomy or laparotomy,
  2) recovery time, and
  3) cosmesis,

  thoracoscopic approach may prove to be an alternative to classical methods for the repair of CDH with good results.